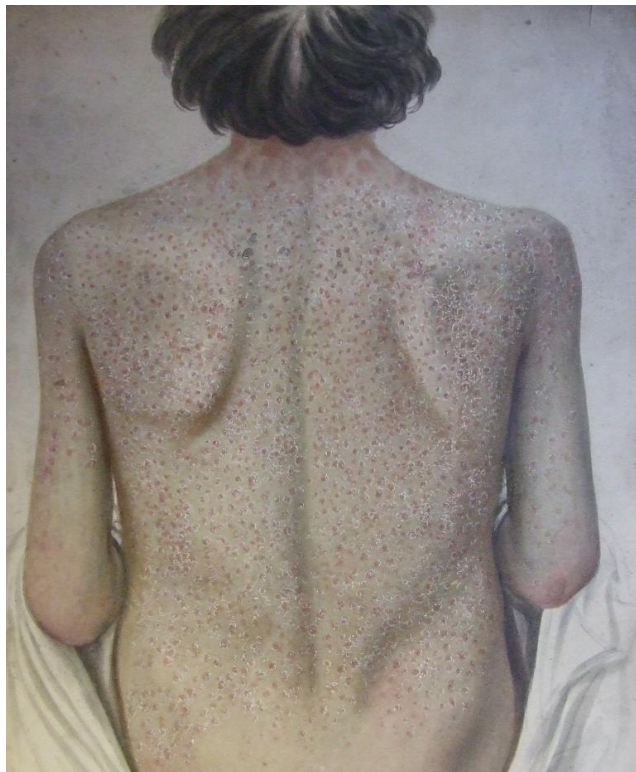


# Medical Illustrations

---

ACC/2014/6



A collection of nineteenth century medical illustrations and photographs.

Catalogued by Harriet Wheelock  
April 2015

**MI**  
**Medical Illustrations**

**Collection**  
**Nineteenth century**

*Extent:*

74 items

*Description:*

A collection of nineteenth century medical illustrations and photographs, mainly showing cases of skin diseases, but also including some other conditions and some surgical illustrations.

*Arrangement:*

The illustrations have been divided into sections by artists, with the exception of the illustrations and photographs commissioned by Wallace Beatty which have been treated as a section on their own. Within each section the illustrations have been arranged alphabetically by title.

*Administrative History:*

It is not clear what the origin of this collection of large nineteenth century medical illustrations is, or if they originally formed one group. The majority of the illustrations relate to skin diseases, and it is clear that part of this collection was commissioned by Wallace Beatty, and seems to have been used by him as teaching aids at the end of the nineteenth century. It is possible that Beatty also collected some of the earlier illustrations, and certainly some have notes identifying the patient's condition which seem to have been added later.

*Access Conditions:*

Access subject to the conditions laid out in the Heritage Centre Access Guidelines

*Reproductions:*

Copying of archive material is subject to the conditions laid out in the Heritage Centre Copying Guidelines.

*Language:*

English

**MI/1**  
**J Connolly**

**Series**  
**[mid-nineteenth century]**

*Extent:*  
13 items

*Creator:*  
Connolly, J.

*Description:*  
Collection of watercolour illustrations of medical cases drawn by J Connolly. The majority of the cases are dermatological, but there are also two surgical illustrations. Each illustration has the name and age of the patient in the bottom left, with Connolly's signature in the bottom right. In a couple of cases the name of the disease has been added in a different hand.

*Arrangement:*  
Items are arranged alphabetically by case name.

<b>MI/1/1</b>	<b>Case of Bridg. McNally</b>	<b>[mid-nineteenth century]</b>
	<i>Extent:</i> 1 page	
	<i>Creator:</i> Connolly, J.	
	<i>Description:</i> [Watercolour] illustration of the case of Bridget McNally, aged 3 years. Image shows body from the naval to the knees with marks and an abnormal growth.	
<b>MI/1/2</b>	<b>Case of Catherine Timmins</b>	<b>[mid-nineteenth century]</b>
	<i>Extent:</i> 1 page	
	<i>Creator:</i> Connolly, J.	

*Description:*

[Watercolour] illustration of the case of Catherine Timmins aged 16. Illustration show [ovaries] presumably removed during surgery. One is greatly enlarged and has been dissected.

**MI/1/3**

**Case of Connor O'Brien**

**[mid-nineteenth century]**

*Extent:*

1 page

*Creator:*

Connolly, J.

*Description:*

[Watercolour illustration] of the case of Connor O'Brien aged 56. Illustration shows right leg from the knee down, there is a large open and infected area on the shin.

**MI/1/4**

**Case of Ds Cahill**

**[mid-nineteenth century]**

*Extent:*

1 page

*Creator:*

Connolly, J.

*Description:*

[Watercolour] illustration of the case of Ds Cahill aged 50. Illustration shows abnormal growth around the rectum.

**MI/1/5**

**Case of Ellen McKeever**

**[mid-nineteenth century]**

*Extent:*

1 page

*Creator:*

Connolly, J

*Description:*

[Watercolour] illustration of the case of Ellen McKeever aged 77. Image shows upper leg with an epithelioma.

**MI/1/6**

**Case of Hugh Conlan**

**[mid-nineteenth century]**

*Extent:*

1 page

*Creator:*

Connolly, J

*Description:*

[Watercolour] illustration of Hugh Conlan aged 27. Image shows the head and neck of Conlan with a number of abnormal growths.

**MI/1/7**

**Case of James Gormley**

**[mid-nineteenth century]**

*Extent:*

1 page

*Creator:*

[Connolly, J]

*Description:*

[Watercolour] illustration of the case of James Gormley, aged 30. Image shows lower left leg with a series of open sores, some of which have been tied closed.

**MI/1/8**

**Case of Joseph Byrne**

**[mid-nineteenth century]**

*Extent:*

1 page

*Creator:*

Connolly, J

*Description:*

[Watercolour] illustration of the case of Joseph Byrne, aged 45. Illustration shows an amputated right arm, with the skin pulled back to reveal the bones, muscles and [growths].

<b>MI/1/9</b>	<b>Case of Js. Courtney</b>  <i>Extent:</i> 1 page  <i>Creator:</i> Connolly, J  <i>Description:</i> [Watercolour] illustration of the case of J[ame]s Courtney aged 11. Illustration shows Courtney's back which is covered in a rash caused by syphilis.	<b>[mid-nineteenth century]</b>
<b>MI/1/10</b>	<b>Case of Mathw. Lynch</b>  <i>Extent:</i> 1 page  <i>Creator:</i> Connolly, J  <i>Description:</i> [Watercolour] illustration of the case of Matthew Lynch aged 59. Images shows profile of the head and shoulders of Lynch, with a large epithelioma under the left eye.	<b>[mid-nineteenth century]</b>
<b>MI/1/11</b>	<b>Case of Mathw. McCormic</b>  <i>Extent:</i> 1 page  <i>Creator:</i> Connolly, J  <i>Description:</i> [Watercolour] illustration of the case of Matthew McCormic aged 76. Image shows head and shoulders of McCormic, with a large growth on the lower lip.	<b>[mid-nineteenth century]</b>

<b>MI/1/12</b>	<b>Case of Mr A.</b>  <i>Extent:</i> 1 page  <i>Creator:</i> Connolly, J  <i>Description:</i> [Watercolour] illustration of the case of Mr A. at the age of 21. Images shows the back, hand and genitals of Mr A, all covered with red marks.	<b>[mid-nineteenth century]</b>
<b>MI/1/13</b>	<b>Case of Philip Andw. Kennedy</b>  <i>Extent:</i> 1 page  <i>Creator:</i> Connolly, J  <i>Description:</i> [Watercolour] illustration of the case of Philip Andrew Kennedy aged 43. Image show an epithlioma of the anus.	<b>[mid-nineteenth century]</b>
<b>MI/1/14</b>	<b>Untitled</b>  <i>Extent:</i> 1 item  <i>Creator:</i> Connolly, J  <i>Description:</i> [Watercolour] illustration of lower arm with skin condition below the elbow.	<b>[mid-nineteenth century]</b>

**MI/2**  
**William Bourke Kirwan**

**1835-1851**  
**Series**

*Extent:*  
34 items

*Creator:*  
Kirwan, William Bourke, [b.1814]

*Description:*  
William Bourke Kirwan was born in Dublin in about 1814, the son of a picture dealer. Kirwan studied art, and exhibited miniatures and water-colours in the Royal Hibernian Academy. Kirwan's chief occupation during the 1830s and 1840s was as an anatomical draftsman and medical illustrator for Dublin's medical professions. In 1852 Kirwan was tried for the murder of his wife at Ireland's Eye. Although found guilty and condemned to death, the evidence was judged not wholly conclusive and the sentence was commuted to transportation for life.

*Arrangement:*  
Items are arranged alphabetically by subject name.

**MI/2/1**

**Case of [unstated]**

**1847**

*Extent:*  
3 items

*Creator:*  
Kirwan, William Bourke, [b.1814]

*Description:*  
Two water-colour illustrations of the same case labelled 'No. 2 Under Operation' and 'No.3 After Operation', the details of the patients name and age have not been completed. Illustrations No. 2 show a side view of young child in a head and shoulder brace, with illustration No. 3 showing a face forward view of the same child after the removal of the brace. There is also a pencil sketch of the same image as in illustration No. 2, there is no indication if this was done by Kirwan at the time, or later by another artist. On the reverse of the same sheet is a pencil sketch of the back view of [the same child] with a heavily



distored neck, this may well be a copy of the missing first illustration from the sequence.

<b>MI/2/2</b>	<b>Case of Anne Fitzimons</b>	<b>1839</b>
	<i>Extent:</i> 2 items	
	<i>Creator:</i> Kirwan, William Bourke, [b.1814]	
	<i>Description:</i> Two water-colour illustrations of the case of Anne Fitzimons, aged 40 years. Illustrations show the discoloured and diseased feet of the patient.	
<b>MI/2/3</b>	<b>Case of Anne Jackson</b>	<b>1838</b>
	<i>Extent:</i> 1 page	
	<i>Creator:</i> Kirwan, William Bourke, [b.1814]	
	<i>Description:</i> Water-colour illustration of the case of Anne Jackson aged 30 years. Images shows lower back to knees of the patient, with a tumor of the anus. Note on back of illustration reads 'No. 34. Stephen's Hospital Portfolio case of Anne Jackson at 30 years. Tumour of the anus. Patient of Surgeon Wilmot'.	
<b>MI/2/4</b>	<b>Case of Anne Leonard</b>	<b>5 May 1851</b>
	<i>Extent:</i> 1 page	
	<i>Creator:</i> Kirwan, William Bourke, [b.1814]	
	<i>Description:</i>	

Water-colour illustration of the case of Anne Leonard, aged 47 years. Illustration shows a diseases and deformed arm.

**MI/2/5**

**Case of Henry Higgins**

**c.1840s**

*Extent:*

2 items

*Creator:*

Kirwan, William Bourke, [b.1814]

*Description:*

Water-colour illustration of the case of Henry Higgins aged six years. Illustration shows a rear view of the legs of Higgins, which are deformed. File also contains an unsigned image which seems to be a frontal view of the same patient.

**MI/2/6**

**Case of James Brenan**

**1840**

*Extent:*

1 page

*Creator:*

Kirwan, William Bourke, [b.1814]

*Description:*

Water-colour illustration of the case of James Brenan aged 32 years. Illustration shows the right arm of the patient with a series of growths and rashes on the skin.

**MI/2/7**

**Case of Jane Caufield**

**1841**

*Extent:*

1 page

*Creator:*

Kirwan, William Bourke, [b.1814]

*Description:*

Water-colour illustration of the case of Jane Caufield aged 15. Illustration shows the head

and shoulders of Caufield, who has a skin disease on her upper-lip, cheeks and nose.

- MI/2/8**                      **Case of John Gallagher**                      **1840**
- Extent:*  
1 page
- Creator:*  
Kirwan, William Bourke, [b.1814]
- Description:*  
Water-colour illustration of the case of John Gallagher, aged 62 years. Image shows lower right leg of Gallagher, with a patch of skin disease on the shin.
- 
- MI/2/9**                      **Case of John Price**                      **1838**
- Extent:*  
1 page
- Creator:*  
Kirwan, William Bourke, [b.1814]
- Description:*  
Water-colour illustration of the case of Joh Price aged 67 years. Illustration shws the right arm of Price, which is marked by a red rash.
- 
- MI/2/10**                      **Case of Kitty Stapelton**                      **4 August  
1848**
- Extent:*  
1 page
- Creator:*  
Kirwan, William Bourke, [b.1814]
- Description:*  
Water-colour illustration of the case of Kitty Stapelton, aged 12 years. Illustration show the head and shoulders of the patient, who has a deformity/injury to the left side of her mouth. Note in the bottom corner of the page reads 'admitted July 26th 1848, drawing made August

4th 1848'. The name of the hospital is not given, but the note is similar to those on drawing identified as coming from the Meath Hospital.

**MI/2/11**                      **Case of Margaret Kells**                      **16 June 1845**

*Extent:*

1 page

*Creator:*

Kirwan, William Bourke, [b.1814]

*Description:*

Water-colour illustration of the case of Margaret Kells, aged 8 years. Illustration shows the head and shoulders of Margaret, with a red rash around the lower face and neck.

Note below the illustration reads '16th June 1845, Meath Hospital'

**MI/2/12**                      **Case of Margaret Tilbery**                      **5 December  
1838,  
9 February  
1839**

*Extent:*

2 items

*Creator:*

Kirwan, William Bourke, [b.1814]

*Description:*

Water-colour illustrations of the case of Margaret Tilbery. In the first illustration, dated 5 December 1838, Margaret's age is given as 10 weeks. The illustration shows the skin around the left eye is badly [infected] and has covered the whole eye socket. The second illustration, dated 9th February 1839, gives Margaret's age as 4 months and 2 weeks. The left eye is now visible although there is still discoloration and skin disease around the eye.

**MI/2/13**

**Case of Peter Byrne**

**2 August  
1847**

*Extent:*

1 page

*Creator:*

Kirwan, William Bourke, [b.1814]

*Description:*

Water-colour of case of Peter Byrne aged 66 years. Illustration shows the lower right leg of the patient, with a patch of skin disease. Note reads 'Admitted July 30th 47, August 2nd 1847 drawing made. Meath Hospital.'

**MI/2/14**

**Case of P Fegan**

**c.1830s**

*Extent:*

1 page

*Creator:*

Kirwan, William Bourke, [b.1814]

*Description:*

Illustration of the case of P Fegan, patient in Jervis St. Hospital under the casre of Surgeon Wallace. Illustrations show Fegan lying on his back reading a book. The upper part of his left leg is badly swollen.

Notes under illustration read 'Case of tumor arising from a blow of a stone above the patella, and also produced a slight affection of the heart. When opened 2 quarts of whey coloured water was extracted from the interior of the body. The disease of the heart was a slight contraction of the pulse. The patella was perfectly free from disease, the femur was diseased on which lay the tumor. The femur was coverd with brain coloured matter - the disease part of the bone was quite soft.'

- |                |   |                  |
|----------------|---|------------------|
| <b>MI/2/15</b> | <b>Case of P Rochfort</b>   | <b>1849</b>      |
|                | <i>Extent:</i><br>1 page  |                  |
|                | <i>Creator:</i><br>Kirwan, William Bourke, [b.1814]   |                  |
|                | <i>Description:</i><br>Water-colour illustration of the case of P Rochfort aged 17.   |                  |
| <b>MI/2/16</b> | <b>Case of Thomas Eames</b>   | <b>1841</b>      |
|                | <i>Extent:</i><br>1 page  |                  |
|                | <i>Creator:</i><br>Kirwan, William Bourke, [b.1814]   |                  |
|                | <i>Description:</i><br>Water-colour illustration of the case of Thomas Eames aged 55 years. Illustration show Eames lying in a bed, with a patch of discoloured and diseased skin on his forehead.          |                  |
| <b>MI/2/17</b> | <b>Case of Thomas Keating</b>   | <b>July 1839</b> |
|                | <i>Extent:</i><br>1 page  |                  |
|                | <i>Creator:</i><br>Kirwan, William Bourke, [b.1814]   |                  |
|                | <i>Description:</i><br>Water-colour illustration of the case of Thomas Keating, aged 12 years. Image shows the diseases and deformed hand of Keating, with other patches of skin discolouration on his arm. |                  |

<b>MI/2/18</b>	<b>Case of Will. McLoughlan</b>	<b>March 1839</b>
	<i>Extent:</i> 1 page	
	<i>Creator:</i> Kirwan, William Bourke, [b.1814]	
	<i>Description:</i> Water-colour illustration of the case of William McLoughlian aged 16. Image shows the naval and upper legs of McLoughlan which are covered with patches of skin disease and scabs.	
<b>MI/2/19</b>	<b>P2 - Dissection of the joint after amputation</b>	<b>c.1840s</b>
	<i>Extent:</i> 1 page	
	<i>Creator:</i> Kirwan, William Bourke, [b.1814]	
	<i>Description:</i> Water-colour illustration of a dissection of a joint, with pencil notes pointing out certain features of the joint.	
<b>MI/2/20</b>	<b>P3</b>	<b>Undated</b>
	<i>Extent:</i> 2 items	
	<i>Creator:</i> Kirwan, William Bourke, [b.1814]	
	<i>Description:</i> Two water-colour images of a foot and ankle both marked P3. One image shows a foot during an operation with the skin pulled back and the muscles and bone exposed, the second shows a swollen foot with a patch of discoloured and diseased skin.	

**MI/2/21 The foot four years and a half after extirpation 1835**

*Extent:*

2 items

*Creator:*

Kirwan, William Bourke, [b.1814]

*Description:*

Two water-colour illustrations showing the foot of a patient after extirpation, which seems to have taken place on the inner edge of the foot below the big toe. The big toe is also missing. One of the illustrations has explanatory notes on the operation.

**MI/2/22 Untitled 1836**

*Extent:*

1 page

*Creator:*

Kirwan, William Bourke, [b.1814]

*Description:*

Water-colour illustration showing a piece of [bone].

**MI/2/23 Untitled 1836**

*Extent:*

1 page

*Creator:*

Kirwan, William Bourke, [b.1814]

*Description:*

Water-colour illustration showing the right leg of a patient. There is a spot below the knee.

**MI/2/24 Untitled 1839**

*Extent:*

1 page



*Creator:*  
Kirwan, William Bourke, [b.1814]

*Description:*  
Water-colour illustration of a brain.

**MI/2/25**                      **Untitled**    **1839**

*Extent:*  
1 page

*Creator:*  
Kirwan, William Bourke, [b.1814]

*Description:*  
Water-colour illustration of a [premature] baby with badly discoloured skin. The umbilical cord and placenta are still attached.

**MI/2/26**                      **Untitled**    **1843**

*Extent:*  
1 page

*Creator:*  
Kirwan, William Bourke, [b.1814]

*Description:*  
Water-colour illustration of [overaies].

**MI/2/27**                      **Untitled**    **Undated**

*Extent:*  
1 page

*Creator:*  
[Kirwan, William Bourke, [b.1814]]

*Description:*  
Water-colour illustration of [a piece of bone and surrounding tissue] possibly by Kirwan.

**MI/3**  
**Wallace Beatty, Adelaide Hospital**

**1890s**  
**Series**

*Extent:*  
21 items

*Creator:*  
Beatty, Wallace, 1853-1923

*Description:*  
Series of water-colour illustrations, and some photographs, of skin diseases produced by Wallace Beatty. Most seem to be cases Beatty treated in the Adelaide Hospital. It seems possible that some of the illustrations were used as teaching aids, and the collection also includes a couple of large charts which deal with the etiological classification of skin diseases.

*Arrangement:*  
Items are arranged alphabetically by subject name.

**MI/3/1                      Actinomycosis of the thigh                      c.1890s**

*Extent:*  
1 page

*Creator:*  
C R

*Description:*  
Water-colour illustration showing a case of actinomycosis of the thigh. Pencil note on back reads 'At site of morphine injection self given'.

**MI/3/2                      Cheloid                      c.1890s**

*Extent:*  
1 page

*Creator:*  
C R

*Description:*

Water-colour illustration of a case of cheloid on the chest. Pencil note on back reads 'Mr Boyle, Carlow, daughter also affected & was in A[delaide] H[ospital].

**MI/3/3**

**Dermatitis herpiformis**

**November  
1895**

*Extent:*

1 page

*Creator:*

A W

*Description:*

Water-colour illustration of a case of dermatitis herpetiformis on the back, seen in the Adelaide Hospital.

**MI/3/4**

**Elephantiasis**

**1895**

*Extent:*

1 page

*Creator:*

A W

*Description:*

Water-colour illustration of a case of Elephantiasis seen by Wallace Beatty in the Adelaide Hospital. Pencil note on back reads 'Reilly - photos too'. NB. these photos were not found with the illustrations.

**MI/3/5**

**Epithelioma**

**c.1890s**

*Extent:*

1 page

*Creator:*

M J F

*Description:*

Water-colour illustration of epithelioma on the back of a hand, in the case of James Barden, aged 80 years, treated in the Adelaide Hospital.

**MI/3/6**                      **Green coloration from dye**                      **c.1890s**

*Extent:*

1 page

*Creator:*

[unknown]

*Description:*

Water-colour illustration showing 'green coloration from dye extracted from stockings by acid sweat between toes'.

**MI/3/7**                      **Lichen moniliformis**                      **c.1890s**

*Extent:*

1 page

*Creator:*

C R

*Description:*

Water-colour illustration of lichen moniliformis on the knee.

**MI/3/8**                      **Milium**                      **c.1890s**

*Extent:*

1 page

*Creator:*

C R

*Description:*

Water-colour illustration of a case of milium on the foot.



- |                |  |                |
|----------------|--|----------------|
| <b>MI/3/12</b> | <b>Pityriasis rubra pilaris</b>  | <b>1896</b>    |
|                | <i>Extent:</i><br>2 items  |                |
|                | <i>Creator:</i><br>R. Forbes, photographerA W  |                |
|                | <i>Description:</i><br>Water-colour illustration of pityriasis rubra pilaris on the arm. Pencil note on back reads 'from same girl as photo'. File also contains a mounted photograph taken by R Forbes for Wallace Beatty of the arm of a patient with pityriasis rubra pilaris, pencil note on back reads 'young woman'.     |                |
| <b>MI/3/13</b> | <b>Pityriasis rubra pilaris</b>  | <b>c.1890s</b> |
|                | <i>Extent:</i><br>5 items  |                |
|                | <i>Creator:</i><br>R. Forbes, photographer   |                |
|                | <i>Description:</i><br>Photographs taken by R Forbes for Wallace Beatty of a young boy boy suffereing from pityriasis rubra pilaris. Three of the photographs, which seem to be taken at the same time are labelled 'Daniel Killiker' on the back, a set of two [later] photographs are labelled 'Daniel Killiker - recovery'. |                |
| <b>MI/3/14</b> | <b>Urticaria pigmentosa</b>  | <b>c.1890s</b> |
|                | <i>Extent:</i><br>1 page   |                |
|                | <i>Creator:</i><br>C R   |                |
|                | <i>Description:</i><br>Water-colour illustration of the face, hands, naval and legs of a patient suffering from  |                |

urticaria pigmentosa, treated by Wallace Beatty.  
Pencil note on back reads 'Paul Swords [ ]  
paper by me. WB'.

**MI/3/15**                      **Etiological classification of cutaneous diseases**                      **c.1890s**

*Extent:*

2 items

*Creator:*

Beatty, Wallace, 1853-1923

*Description:*

One board and one large paper sheet with details of the classification of cutaneous diseases, possibly used as a teaching aid by Beatty.

**MI/3/16**                      **Case of Myxoedema**                      **c.1890s**

1 item

*Creator:*

[unknown]

*Description:*

Two photographs mounted on card, labelled 'before treatment' and 'after treatment' of a female patient suffering from myxoedema.

**MI/4**

**William Lover**

**[mid-  
nineteenth  
century]**

*Extent:*  
5 items

*Creator:*  
Lover, William

*Description:*  
Five watercolour illustrations, 3 signed by Lover, showing [anatomical dissections]. Two of the illustrations have 'Dr Churchill, 136 Stephen's Green' written on the back.



**MI/5**

**Case of Eliza Moffat**

**September  
1872**

*Extent:*

1 item

*Creator:*

Burnside, James H,

*Description:*

Illustration of the case of Eliza Moffat, aged 35, treated at the Adelaide Hospital. Note reads 'Intimately mixed medullary cancer with enchondroma. The tumor was encysted movable and pulsatile. Removed by B W R in Sept. 1872. Wound healed by the end of following Nov. Vide Dub. Monthly Journal for 1st Jan. 1873.

**MI/6**

**William Cookson**

**November  
1835**

*Extent:*  
2 items

*Creator:*  
Cookson, William,

*Description:*  
Watercolour and pencil illustration by Cookson  
[of eyeballs].

MI/7

J.Ms Case

[mid-  
nineteenth  
century]

*Extent:*  
1 page

*Creator:*  
B W R

*Description:*

Watercolour illustration of the heart and lungs following dissection, notes on illustration read 'Dilated right ventricle which forms the apex of the heart. Pulmonary artery of very large calibre. Aorta of very reduced size. Two pulmonary veins open into the right auricle which is also dilated. The caevae also open into the auricle as usual. Lungs congested. Pleurae thickened. The foramen ovale was open in the heart.'

**MI/8**

**[Unknown]**

**[mid-  
nineteenth  
century]**

*Extent:*  
2 items

*Creator:*  
[unknown]

*Description:*  
Two water-colour illustrations, by different artists. One shows the back of a patient suffering from skin disease, the other a patient with epithelioma of the anus.